

# Influence of Voxel Size in the Diagnostic Ability of Cone Beam Tomography to Evaluate Simulated External Root Resorption

Gabriela Salatino Liedke, BDS,\* Heloísa Emília Dias da Silveira, BDS, MSc, PhD,\*  
Heraldo Luis Dias da Silveira, BDS, MSc, PhD,\* Vinícius Dutra, BDS, PhD,<sup>†</sup> and  
José Antônio Poli de Figueiredo, BDS, MSc, PhD<sup>‡</sup>

## Abstract

This study assessed in vitro the diagnostic ability of cone beam computed tomography (CBCT) scans with different voxel resolutions in the detection of simulated external root resorption (ERR). For that purpose, 59 teeth were viewed through iCAT tomography (Imaging Sciences International, Inc, Hatfield, PA) following three protocols in which the variation was the voxel resolution (0.4, 0.3, and 0.2mm). A calibrated examiner blinded to the protocol assessed the images through the i-CAT View software (Imaging Sciences International, Inc). The chi-square statistical analysis did not show associations between voxel resolution, section plane, size of cavity, and radicular third. Sensitivity and specificity values were similar. However, likelihood ratio values of 6.4 for a 0.4-mm voxel, 16 for a 0.3-mm voxel, and 12 for a 0.2-mm voxel were found. It was concluded that CBCT is a reliable method for the investigation of simulated ERR, and a 0.3-mm voxel appeared to be the best protocol, associating good diagnostic performance with lower X-ray exposure. (*J Endod* 2009;35:233–235)

## Key Words

Cone beam computed tomography, diagnosis, external root resorption

From the \*Department of Surgery and Orthopedics, School of Dentistry, Federal University of Rio Grande do Sul (UFRGS), Brazil; <sup>†</sup>CDI Imaging Diagnosis Centre; and <sup>‡</sup>Post-Graduate Program in Dentistry, Pontifical Catholic University of Rio Grande do Sul, Rio Grande do Sul, Brazil.

Address requests for reprints to Dr José Antônio Poli de Figueiredo, Post-Graduate Program in Dentistry, Pontifical Catholic University of Rio Grande do Sul—PUCRS, Av. Ipiranga 6681 Prédio 6 sala 206, CEP 90619-900 Porto Alegre, RS, Brazil. E-mail address: [jose.figueiredo@pucrs.br](mailto:jose.figueiredo@pucrs.br). 0099-2399/\$0 - see front matter

Copyright © 2008 American Association of Endodontists. doi:10.1016/j.joen.2008.11.005

External tooth resorption is a multifactorial process of irreversible structural loss that may lead to the loss of the tooth (1, 2). The diagnosis is based on clinical and radiographic examination (3). Nevertheless, conventional radiographs produce false-negative results in 51.9% and false-positive results in 15.3% of cases investigated (4). It has been shown that lesions under 0.6 mm in diameter and 0.3 mm in depth are not detected by conventional periapical radiography (5, 6).

The main difficulty in the radiographic diagnosis is encountered when the lesions are on the buccal or lingual tooth surfaces (7). Aiming to evaluate how the elimination of structure superimposition improves visualization, da Silveira et al (8) conducted an in vitro study and observed that multislice computed tomography (MSCT) scans offer high sensitivity and specificity to the detection of simulated cavities on the buccal surface of axial tooth sections, except for small cavities present in the apical third.

Diagnostic efficiency and correct characterization of the location and the size of tooth resorption on the root surface are essential aspects to the definition of the adequate therapeutic approach and eventually to success in treatment (6). In this sense, three-dimensional images have proved to be important tools in dental practice. Some studies have reported the use of MSCT for this purpose, although more recently cone beam computed tomography (CBCT) scans have shown other advantages, such as (1) the presence of a collimator, which confines irradiation to the area of study; (2) the isotropic nature of voxels, which affords reconstructions of the same quality of the original image; (3) the speed of conduction (between 10 and 70 seconds); and (4) the low radiation dose the patient is submitted to (around 1/60 of the MSCT dose) (9–13). Another advantage is that voxel size bears a positive correlation with image quality and exposure dose.

The aim of imaging in dentistry is to promote the combined advantages of early diagnosis and reduced exposure of patients to x-rays. With this in mind, the present study was designed to evaluate the diagnostic capacity of CBCT scans to detect external root resorption on the buccal root surface. The experimental variables were cavity size, location on the radicular third, visualization plan (frontal, sagittal, and axial), and voxel resolution adopted.

## Materials and Methods

Sixty human mandibular incisors from the Endodontics Department tooth bank of the School of Dentistry were randomly numbered from 1 to 60. The teeth were not sectioned, but their root portions were divided into thirds: cervical, middle, and apical. A total of 180 thirds was obtained.

For each root third (cervical, middle, and apical), there were 4 simulation possibilities: small, medium, or large cavity or no cavity. Therefore, there were 12 possible combinations, and, for each combination (third × size), 15 teeth were randomly selected.

To simulate external root resorption, the teeth were placed in plaster bases, and cavities of 0.6, 1.2 or 1.8 mm in diameter and 0.3, 0.6 or 0.9 mm in depth (small, medium and large cavities) were drilled according to a protocol reported in the literature (5, 6, 14, 15). The cavities were drilled on the buccal surfaces with high-speed and round burs 0.6, 1.2, and 1.8 mm in diameter (KG, Sorensen, Brazil) and the

assistance of a pneumatic engine (Roll Air III, Kavo do Brasil, Brazil) adapted to a device that ensured the accuracy of the diameter and the depth of the cavity. Simulations in the cervical, middle, and apical thirds of each tooth root were made randomly. Of the 60 teeth in the original sample, one was lost because of fracture at the time of removal from the plaster base. The 59 remaining teeth, divided into two groups of 20 specimens each and one group of 19 specimens, were fixed in 1-cm thick wax plates and placed on the desk of the i-CAT tomography device (Imaging Sciences International, Inc, Hatfield, PA; 120 kVp, 3-8 mA) for image acquisition. The wax simulates the interference of the soft tissues avoiding differences in density between air and teeth. This reduces artifacts in the image. Axial, frontal, and sagittal sections were obtained according to three protocols depending on the voxel resolution desired: 0.4-mm voxel (8-cm field of view [FOV], 20 seconds for acquisition), 0.3-mm voxel (8-cm FOV, 20 seconds for acquisition), and 0.2-mm voxel (8-cm FOV, 40 seconds for acquisition). Images were analyzed by using the i-CAT View software (Imaging Sciences International, Inc).

Images were analyzed by a blinded, previously calibrated radiologist. Calibration consisted of identification of the existence of external root resorption in 10 tomograms that did not belong to the study sample for each voxel resolution. At a 15-day interval, the same observation was repeated. Results at the two time periods were evaluated using kappa statistics to check intraobserver reproducibility. The values obtained for kappa were above 0.73.

The three voxel resolutions (0.4, 0.3, and 0.2 mm) were analyzed independently for association with the three planes (axial, frontal, and sagittal), resorption sizes (small, mid-sized, and large), and its root location (cervical, middle and apical third) by the chi-square test. Significance was established at 5%.

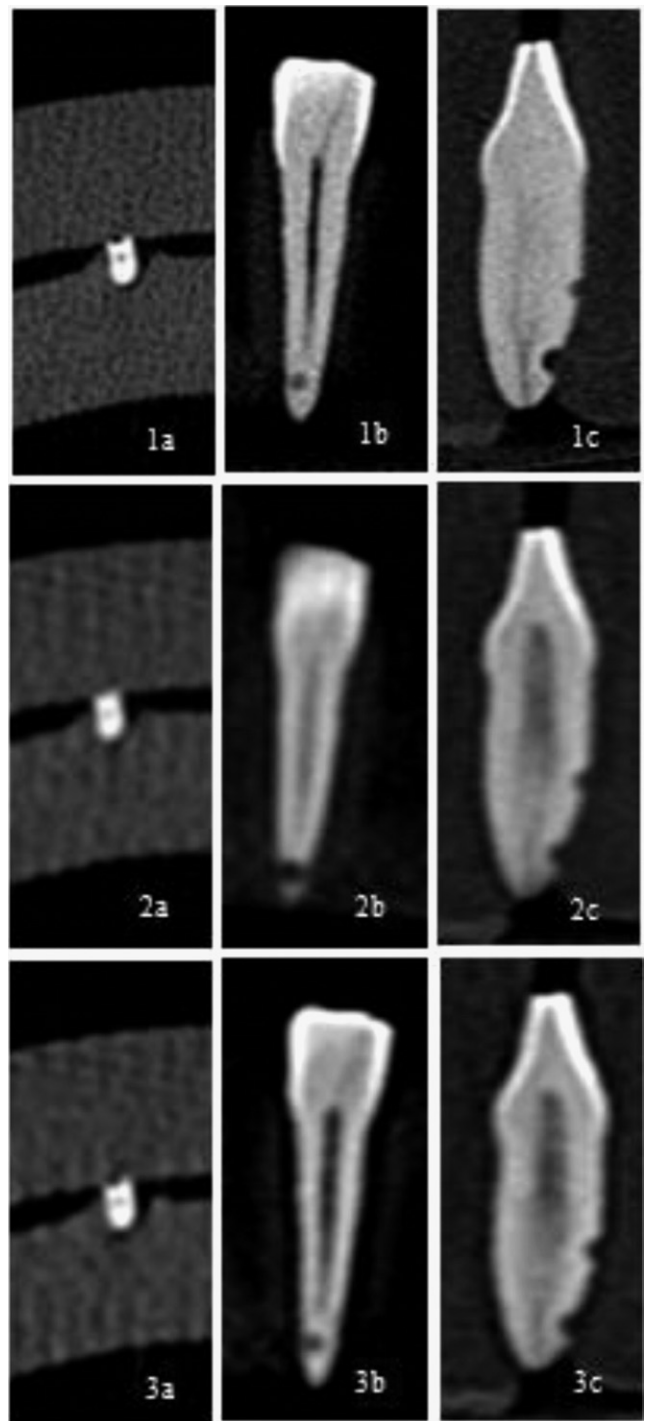
**Results**

Figure 1 shows the images of tomographic sections for each voxel resolution. Table 1 shows the number of resorptions identified in the 131 resorptions simulated, for the section plane used, the root third involved, and the cavity size for each voxel resolution studied, respectively. Tables 1 and 2 also show the chi-square test results, which did not show any association between voxel size (0.4, 0.3, or 0.2 mm) used in imaging and the tomographic plane (axial, frontal, or sagittal), cavity size (small, medium, or large), or with the location of resorption on the radicular third (apical, middle, or cervical) ( $p > 0.05$ ).

The diagnostic capacity of CBCT scans to detect simulated external root resorptions was tested. The results obtained indicated that CBCT sensitivity and specificity values were similar and did not depend on the voxel resolution adopted. Nevertheless, the likelihood ratio was 6.4 for the 4.0-mm voxel, 16 for the 0.3-mm voxel, and 12 for the 0.2-mm voxel (Table 2).

**Discussion**

In root resorption cases, either invasive cervical (16) or inflammatory (17), the sooner the treatment is commenced, the less severe are the short-term consequences. Therefore, the early diagnosis of root resorption is a key aspect to treatment success. Digital radiographic imaging systems have introduced many potential benefits to endodontic practice (18). The evaluation of tooth resorptions using CBCT scans is confined to the description of clinical cases in which the technique was used solely during the three-dimension planning in the treatment of lesions previously diagnosed by means of radiographic investigation (10). In light of the importance of the early diagnosis for the success of treatment of this pathological process, this study aimed at assessing CBCT scans in the diagnoses of simulated external root resorptions of different sizes and locations in the vestibular root surface.



**Figure 1.** Root sections showing the presence of simulated root resorption on the apical third visualized with the different voxel resolutions adopted. With the 0.2-mm voxel: axial plane (1a), frontal plane (1b), and sagittal plane (1c); with the 0.3-mm voxel: axial plane (2a), frontal plane (2b), and sagittal plane (2c); and with the 0.4-mm voxel: axial plane (3a), frontal plane (3b), and sagittal plane (3c).

Previous studies have shown that conventional radiographs fail to efficiently diagnose external root resorptions. This difficulty is mainly expressed in the occurrence of small defects located on the buccal or lingual surfaces (4-7).

da Silveira et al (8) investigated the MSCT technique and observed high sensitivity and specificity for simulated external resorptions on the

**TABLE 1.** Simulated Root Resorptions Identified from a Total of 131 Cavities Considering the Tomographic Plane, Cavity Size, and Location on the Root Third and Significance of the Respective Chi-Square Test for Each Association (p Value)

Association Voxel	Tomographic plane			Cavity size			Root third		
	Axial	Frontal	Sagittal	Small	Medium	Large	Apical	Middle	Cervical
0.4	121	128	131	122	131	127	123	130	127
0.3	126	129	130	124	129	132	128	129	128
0.2	127	129	131	126	130	131	130	130	127
Chi-square test	p = 0.998571			p = 0.99826			p = 0.997397		

buccal root surface. Nevertheless, low sensitivity was verified, with significant statistical difference, when small resorptions located on the apical third were analyzed separately. Conversely, the results obtained in the present study, for specificity and sensitivity, were very good, although without statistically significant differences for cavity visualization, independently of cavity size, location, or plane analyzed.

The results of the diagnostic performance tests revealed values that are similar for sensitivity and specificity between the different voxel resolutions adopted. The likelihood ratio showed that the 0.3- and 0.2-mm voxel resolutions were better as compared with the 0.4-mm voxel resolution, (16, 12, and 6.4, respectively). This shows the greater probability of correctly identifying cavities when the image is acquired using the first two voxel resolution parameters.

Apart from the technical advantages concerning the equipment and the quality of the images obtained (11–13), the most substantial benefit in preferring CBCT to MSCT scans is the lower exposure to x-rays imposed on the patient. Some authors report a decrease of up to 13 times in dosages received (9, 16–18).

The CBCT equipment presents oscillations in the radiation dose emitted, depending on the device model and on the protocol adopted, especially because of the variations in scanning time (19). Similarly, the radiation dose is directly linked to the number of sections. Thus, it is advised to request the smallest possible number of sections for the diagnosis (12). The present study shows that the three voxel resolutions adopted (0.4, 0.3, and 0.2 mm) produced the same results for the diagnosis of cavities that simulate external root resorptions. Yet, this diagnosis was made easier when the 0.3- or 0.2-mm voxel resolutions were used, as the likelihood ratio results confirm. Therefore, for the investigation of this pathology, the best approach would include a CBCT scan with 0.3-mm voxel resolution because the protocol offers the same performance in diagnosis as the 0.2-mm voxel resolution but with shorter scanning time, which reduces patient exposure to x-rays.

**TABLE 2.** Results of Diagnostic Performance Tests According to Voxel Resolution

Test (%)	Voxel resolution		
	0.4	0.3	0.2
Sensitivity	96	97	97
Specificity	85	94	92
Positive predictive value	95	98	97
Negative predictive value	88	92	92.5
Positive likelihood ratio	6.4	16	12

### Conclusion

CBCT is a safe method to investigate external root resorptions, with excellent specificity and sensitivity. The 0.3-mm voxel resolution is the best configuration because it associates great diagnostic performance with lower patient exposure to x-rays.

### References

- Bakland LK. Root resorption. *Dent Clin N Am* 1992;36:491–507.
- Freitas A, Rosa JE, Souza IF. *Radiologia Odontológica*. 5th ed. São Paulo: Artes Médicas; 2000.
- Kim E, Kim KD, Roh BD, Cho YS, Lee SJ. Computed tomography as a diagnostic aid for extracanal invasive resorption. *J Endod* 2003;29:463–5.
- Nance RS, Tyndall D, Levin LG, Trope M. Diagnosis of external root resorption using TACT (tuned-aperture computed tomography). *Endod Dent Traumatol* 2000;16:24–8.
- Andreasen FM, Sewerin I, Mandel U, Andreasen JO. Radiographic assessment of simulated root resorption cavities. *Endod Dent Traumatol* 1987;3:21–7.
- Goldberg F, De Silvio A, Dreyer C. Radiographic assessment of simulated external root resorption cavities in maxillary incisors. *Endod Dent Traumatol* 1998;14:133–6.
- Borg E, Kallqvist A, Grondahl K, Grondahl HG. Film and digital radiography for detection of simulated root resorption cavities. *Oral Surg Oral Med Oral Pathol Oral Radiol Endod* 1998;86:110–4.
- da Silveira HL, Silveira HE, Liedke GS, Lermen CA, Dos Santos RB, de Figueiredo JA. Diagnostic ability of computed tomography to evaluate external root resorption in vitro. *Dentomaxillofac Radiol* 2007;36:393–6.
- Mah JK, Danforth RA, Bumann A, Hatcher D. Radiation absorbed in maxillofacial imaging with a new dental computed tomography device. *Oral Surg Oral Med Oral Pathol Oral Radiol Endod* 2003;96:508–13.
- Cohenca N, Simon JH, Mathur A, Malfaz JM. Clinical indications for digital imaging in dento-alveolar trauma. Part 2: root resorption. *Dent Traumatol* 2007;23:105–13.
- Swennen GR, Schutyser F, Barth EL, De Groeve P, De Mey A. A new method of 3-D cephalometry. Part I: the anatomic Cartesian 3-D reference system. *J Craniofac Surg* 2006;17:314–25.
- Scarfe WC, Farman AG, Sukovic P. Clinical applications of cone-beam computed tomography in dental practice. *J Can Dent Assoc* 2006;72:75–80.
- Holberg C, Steinhäuser S, Geis P, Rudzki-Janson I. Cone-beam computed tomography in orthodontics: benefits and limitations. *J Orofac Orthop* 2005;66:434–44.
- Chapnick L. External root resorption: an experimental radiographic evaluation. *Oral Surg Oral Med Oral Pathol* 1989;67:578–82.
- Hintze H, Wenzel A, Andreasen FM, Swerin I. Digital subtraction radiography for assessment of simulated root resorption cavities. Performance of conventional and reverse contrast modes. *Endod Dent Traumatol* 1992;8:149–54.
- Hiremath H, Yakub SS, Metgud S, Bhagwat SV, Kulkarni S. Invasive cervical resorption: a case report. *J Endod* 2007;33:999–1003.
- Hommeze GM, Browaeys HA, De Moor RJ. Surgical root restoration after external inflammatory root resorption: a case report. *J Endod* 2006;32:798–801.
- Nair MK, Nair UP. Digital and advanced imaging in endodontics: a review. *J Endod* 2007;33:1–6.
- Ludlow JB, Davies-Ludlow LE, Brooks SL. Dosimetry of two extraoral direct digital imaging devices: NewTom cone beam CT and Orthophos Plus DS panoramic unit. *Dentomaxillofac Radiol* 2003;32:229–34.